
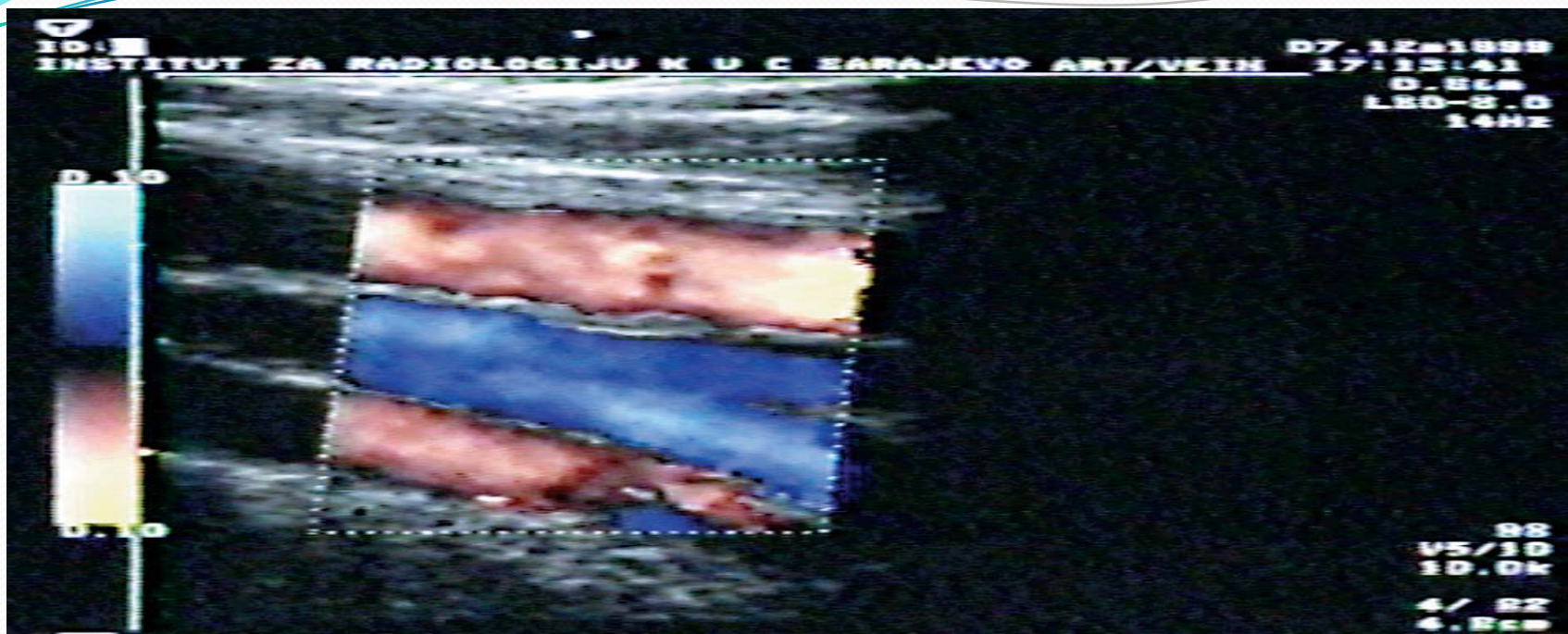


Prezentacija za dopler na krvni sadovi

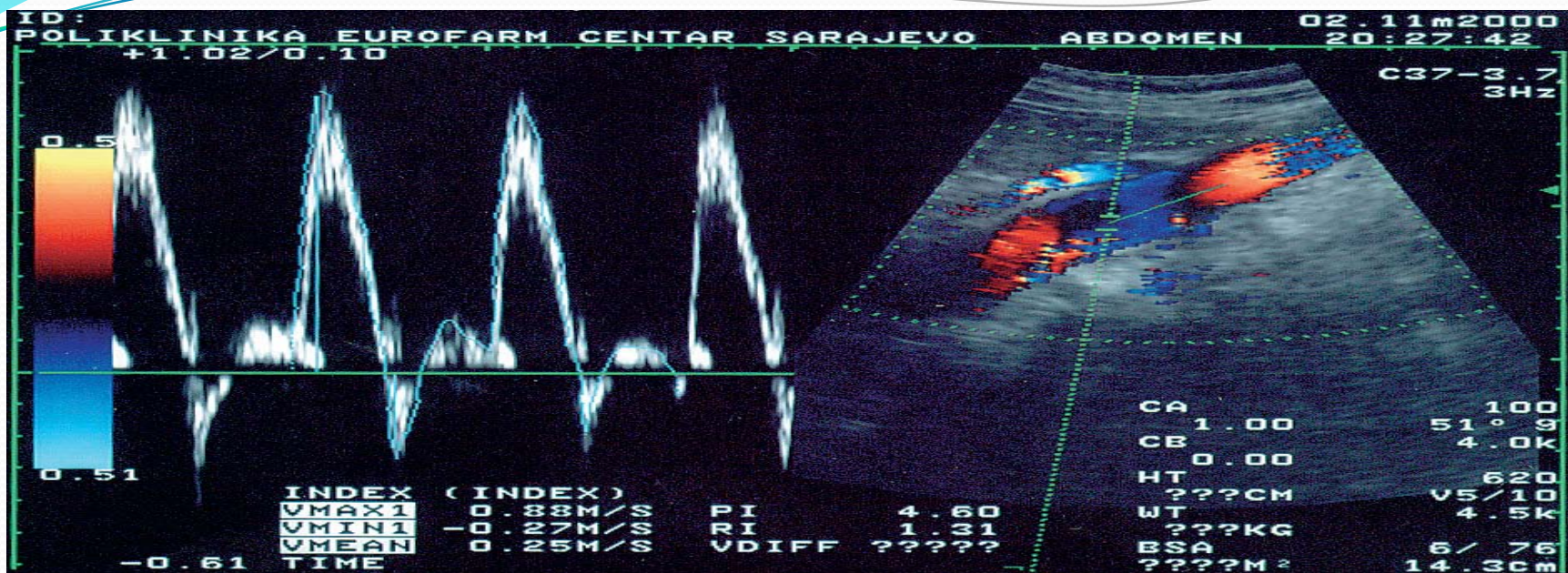Edukacija obavena vo Bolnica Tokuda – Sofija, R. Bugarija
od 16.11 – 12.12.2014

Dr. Snezana Matovic - spec. internist

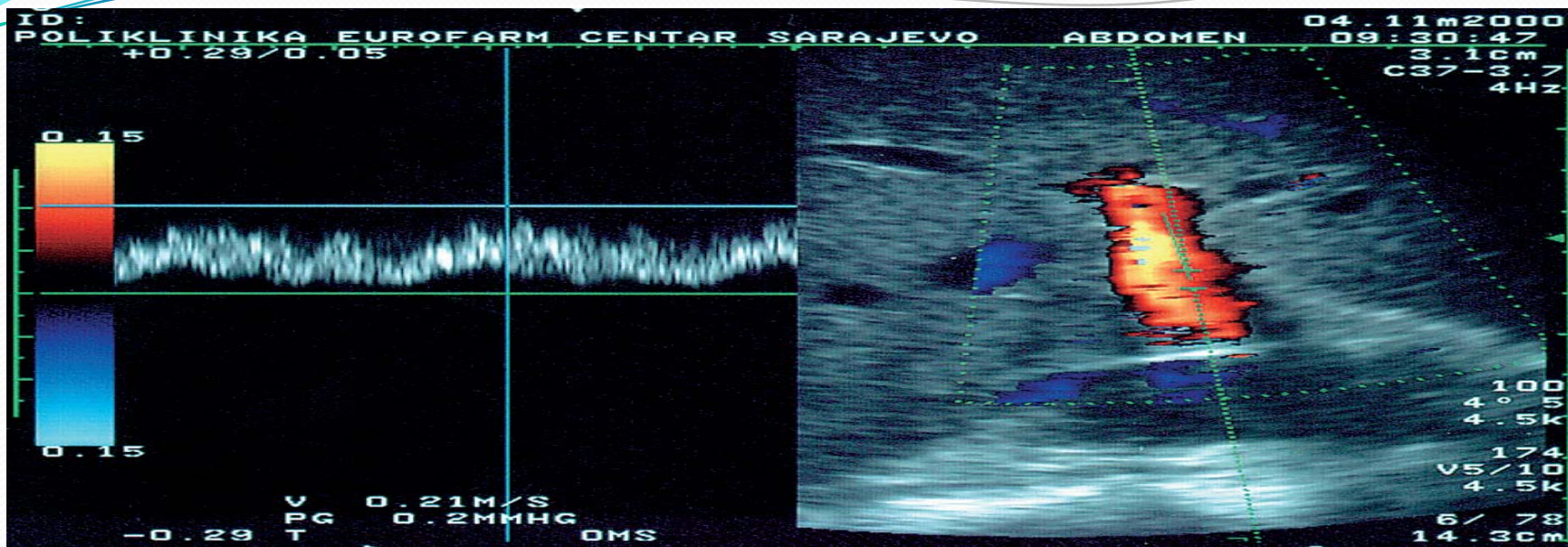
- 
- Za vreme na obukata za dopler na periferni krvni sadovi se zapoznav so slednata patologija na perifernite krvni sadovi:



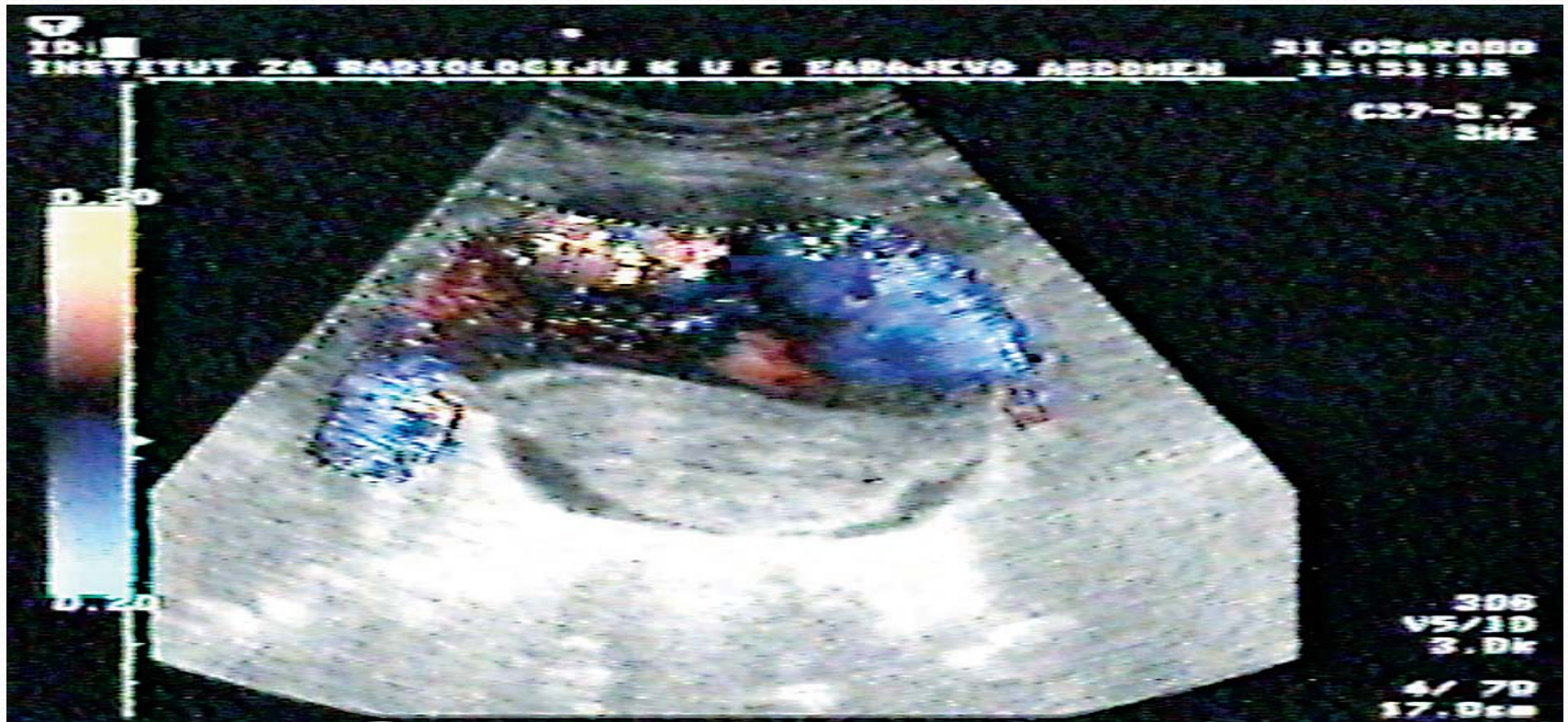- Sematski prikaz na normalen volume na krvni sadovi



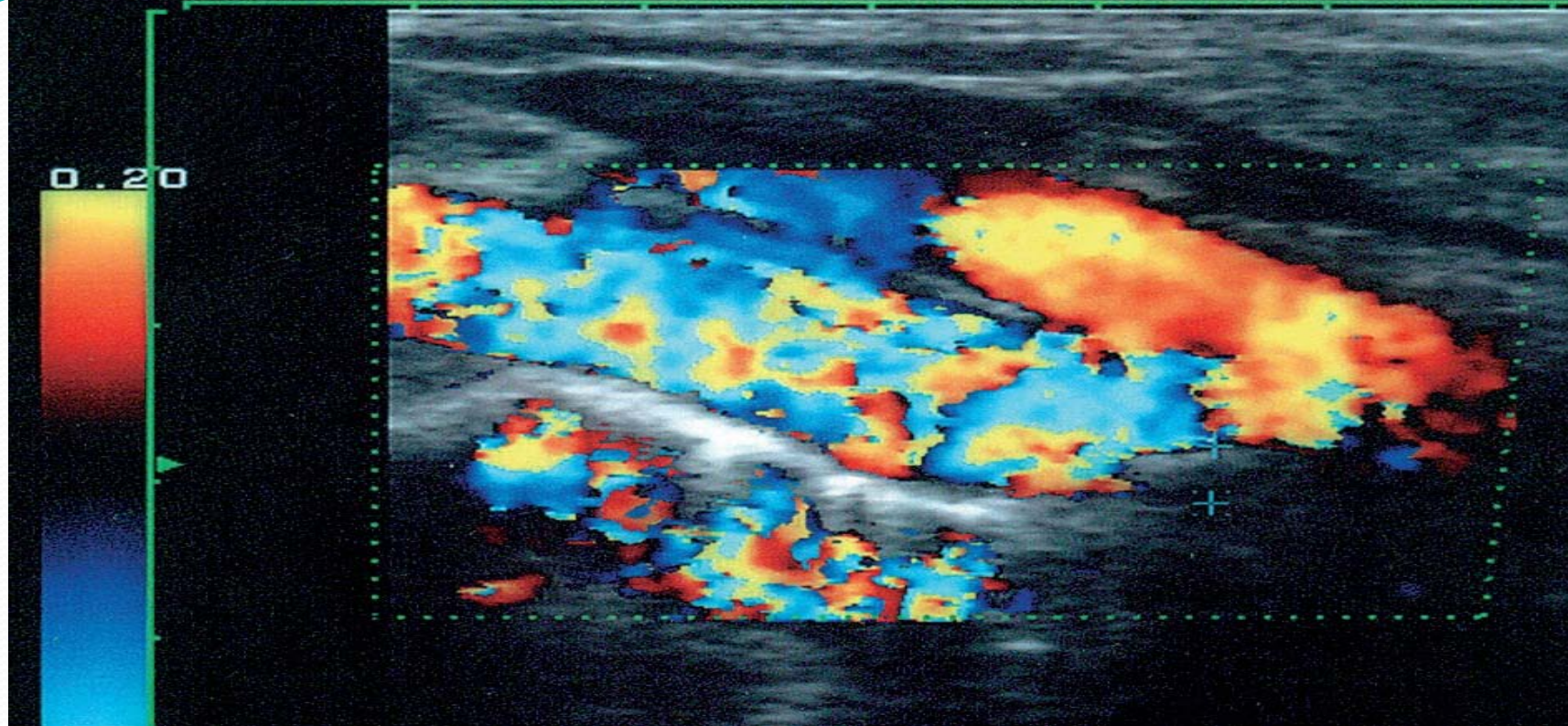
- Sematski prikaz na normalen trifazicen tip na spektar kaj A.A.



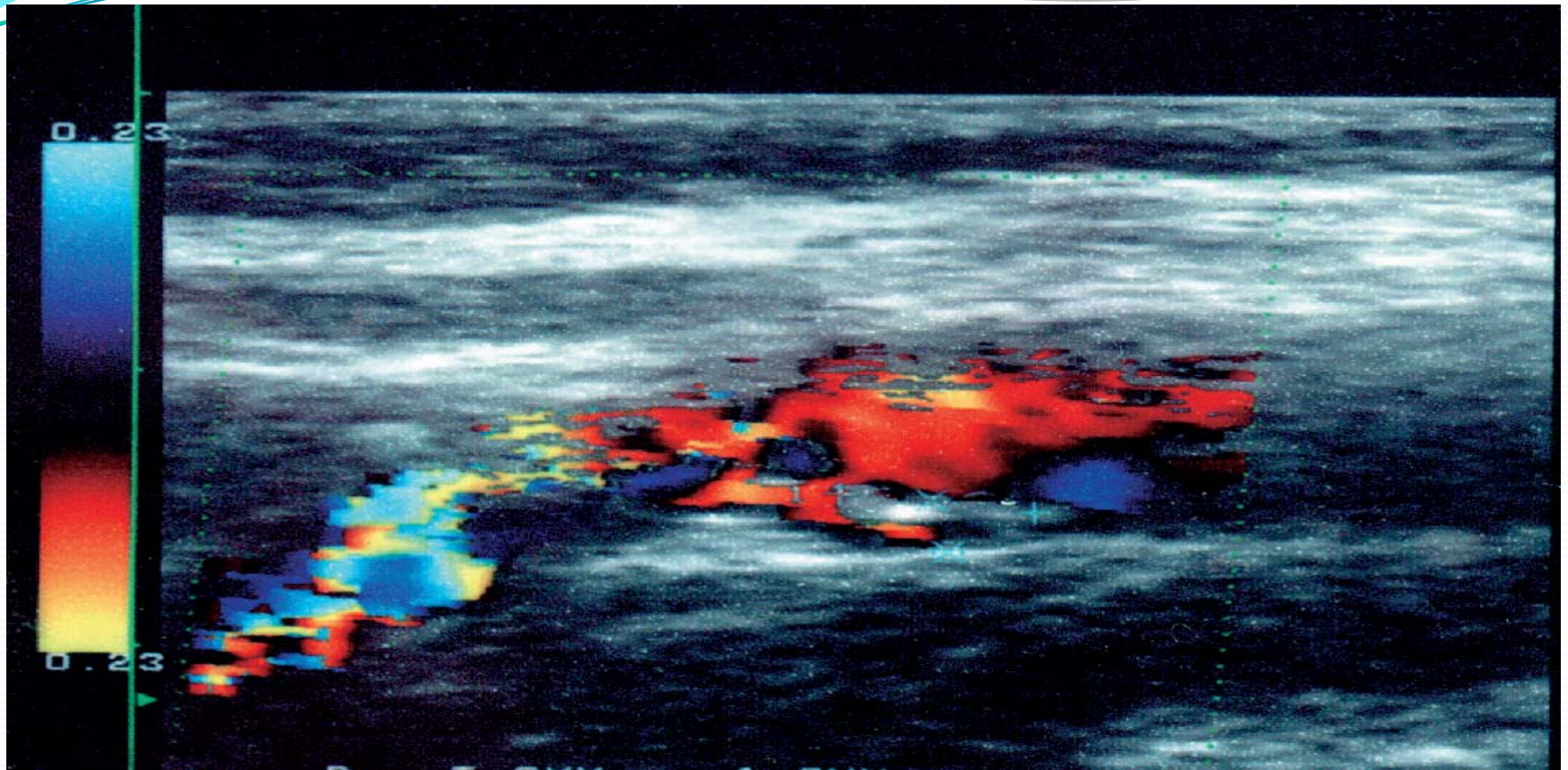
- Sematski prokaz na vena so sreden kalibar



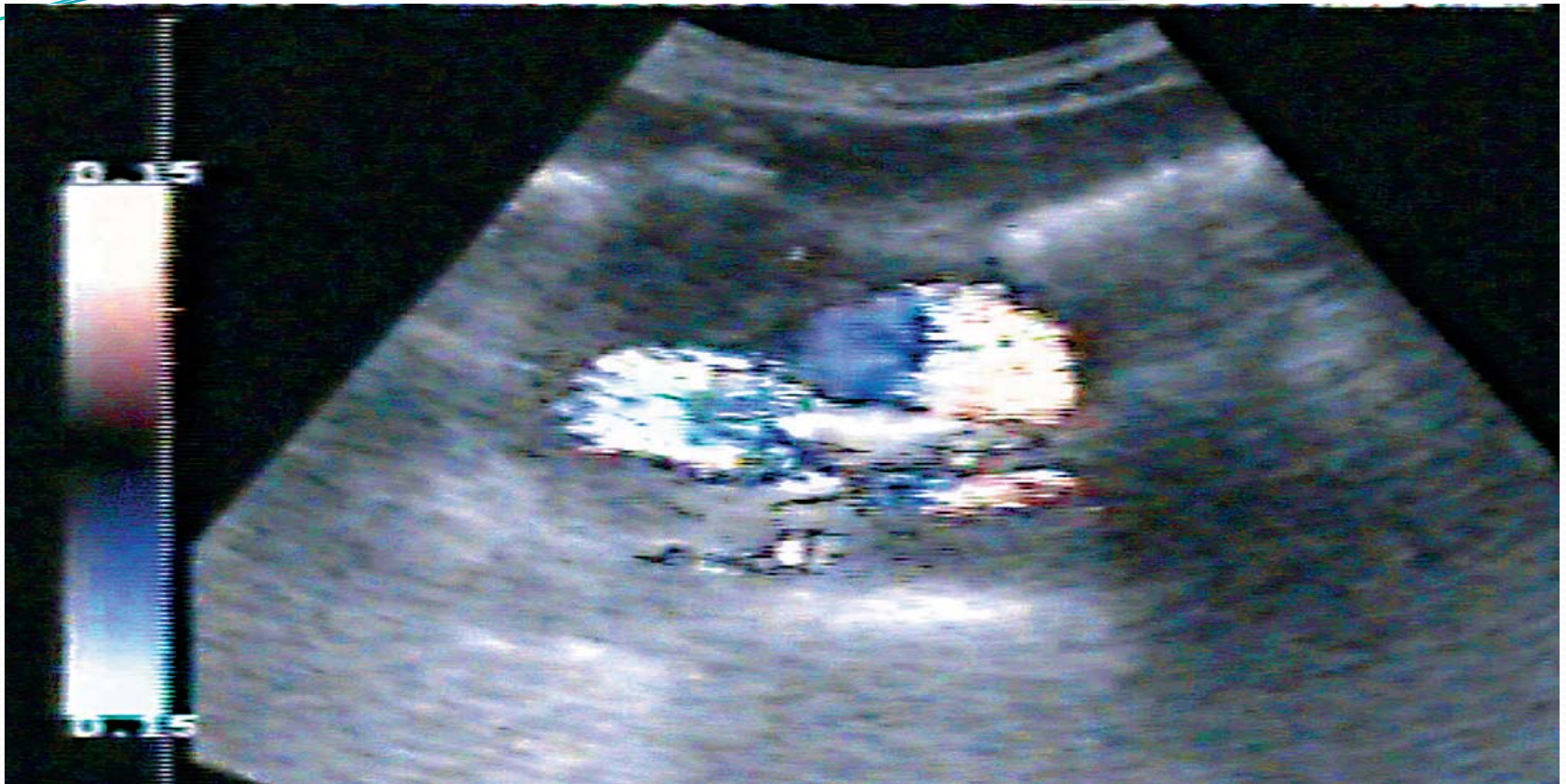
- Sematski prikaz na turbulenten protok kaj dilatiran krven sad.



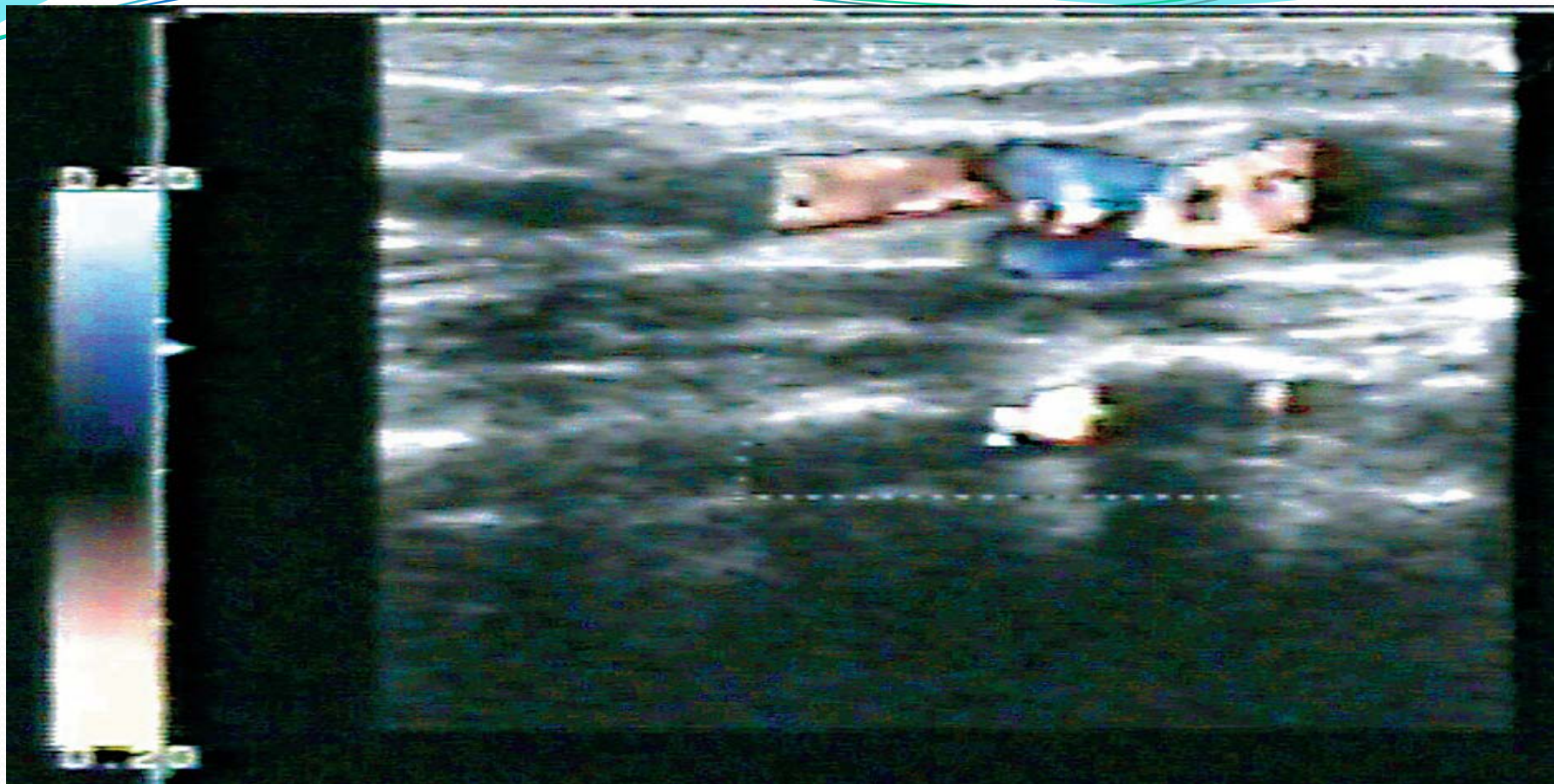
- Sematski prikaz kaj insufientio bulbus aorte



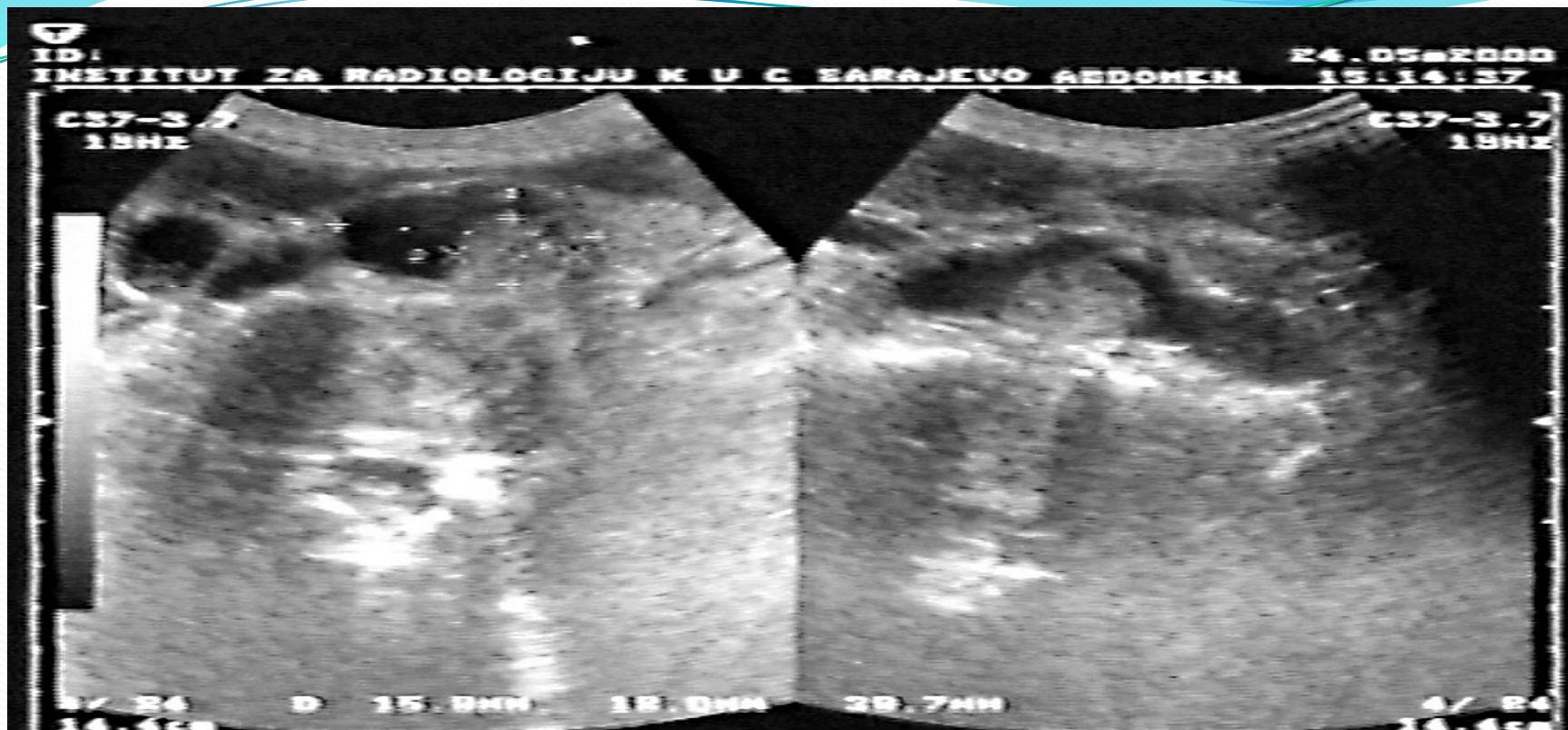
- Sematski prikaz kaj stenoza na aorta abdominalis



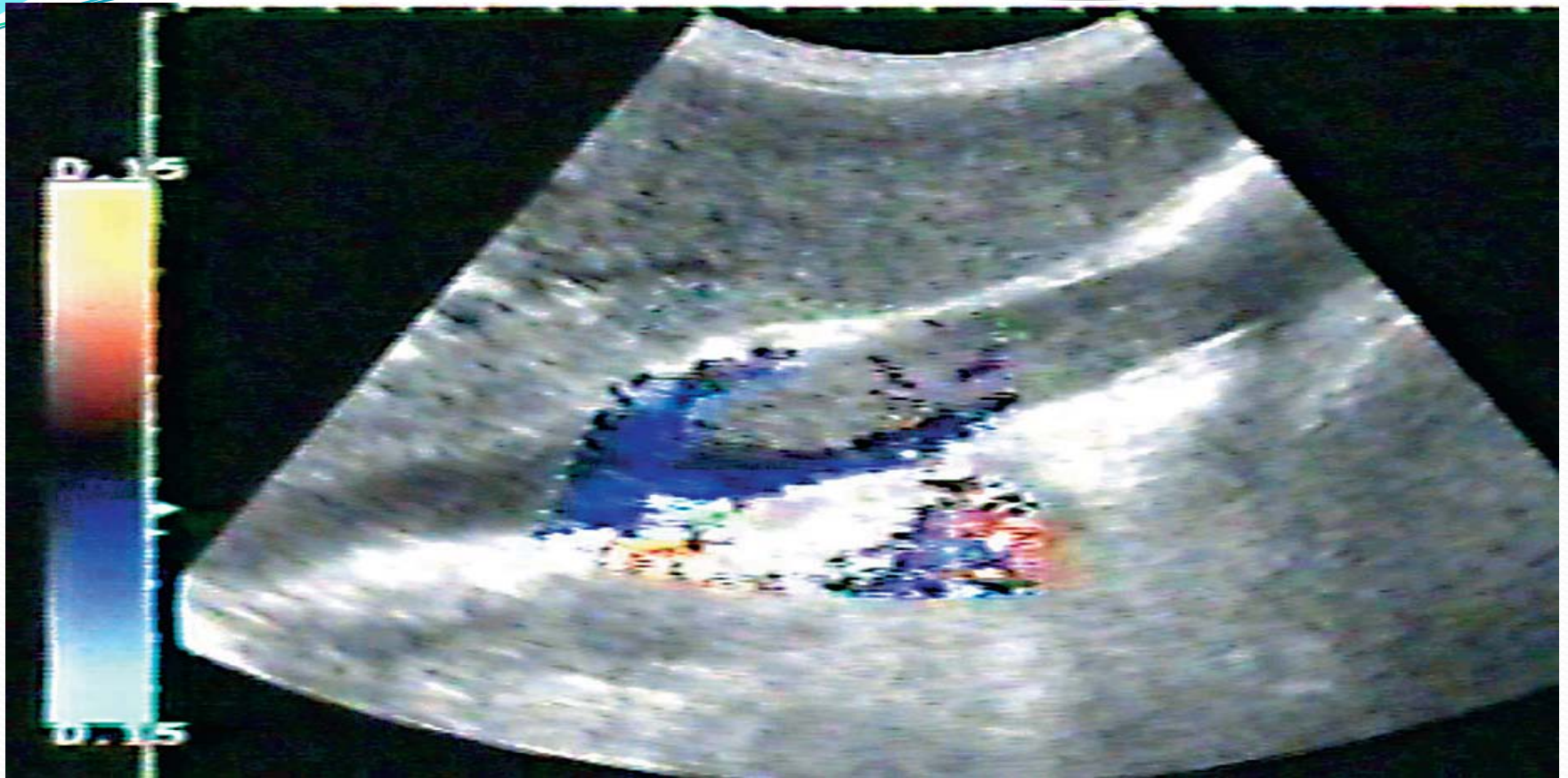
- Sematski prikaz na aneurizma na aorte abdominalis



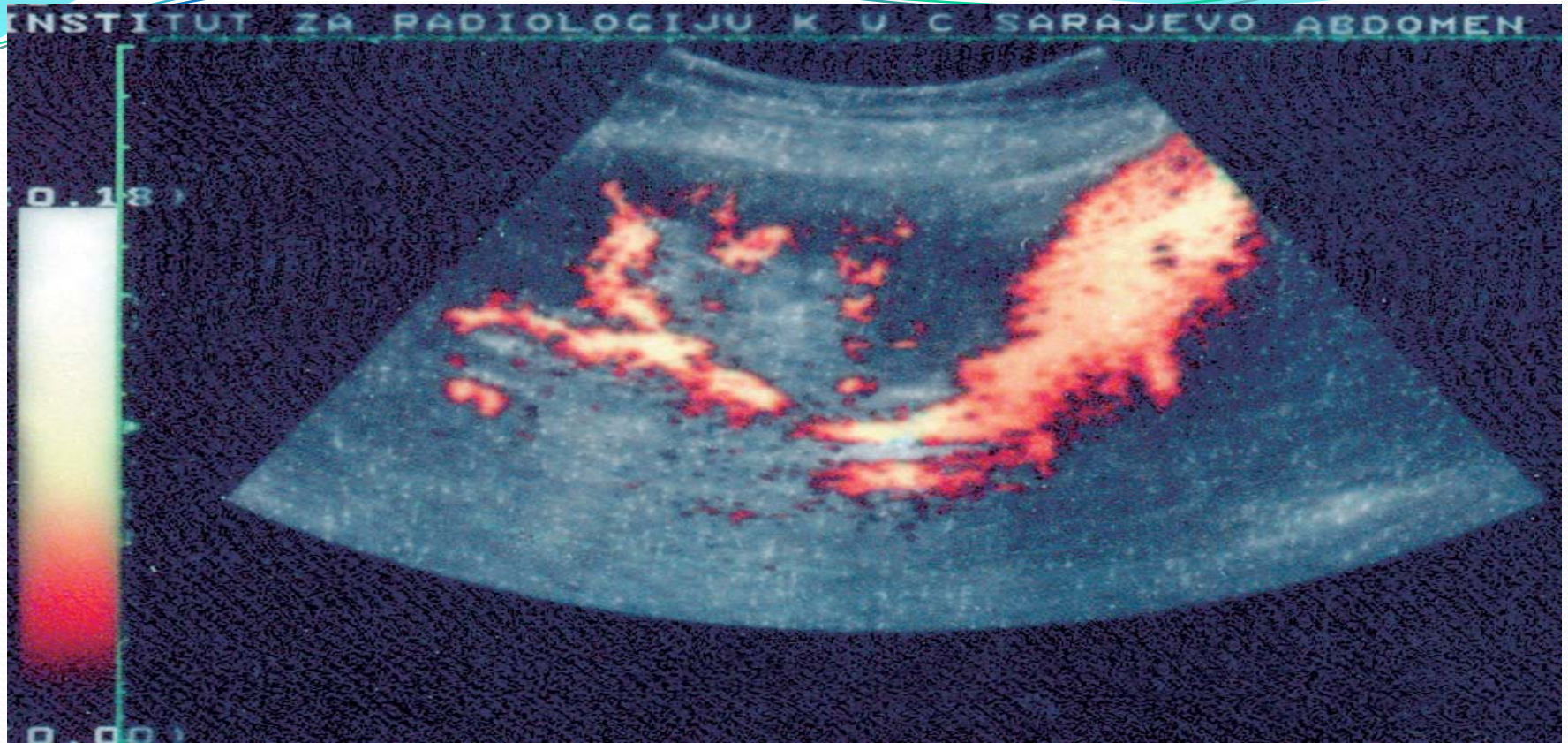
- Sematski prikaz na ulcerozna plaka



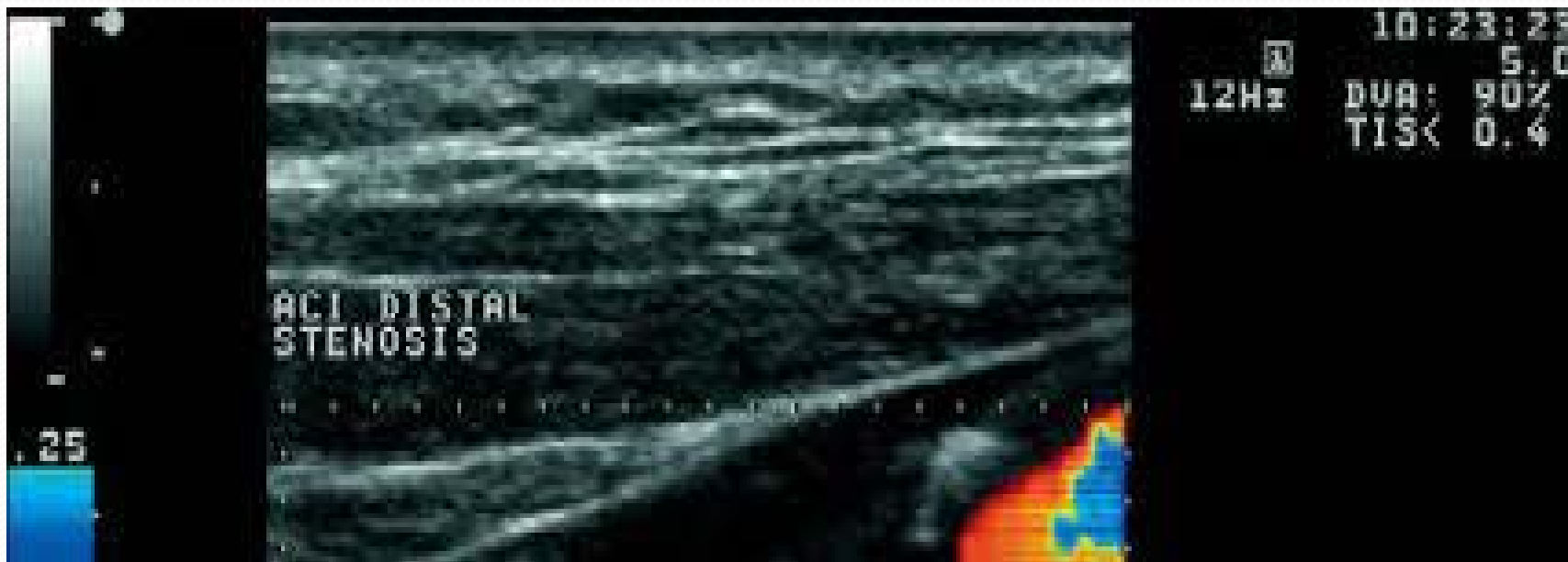- Sematski prikaz na tromboza na A.A.



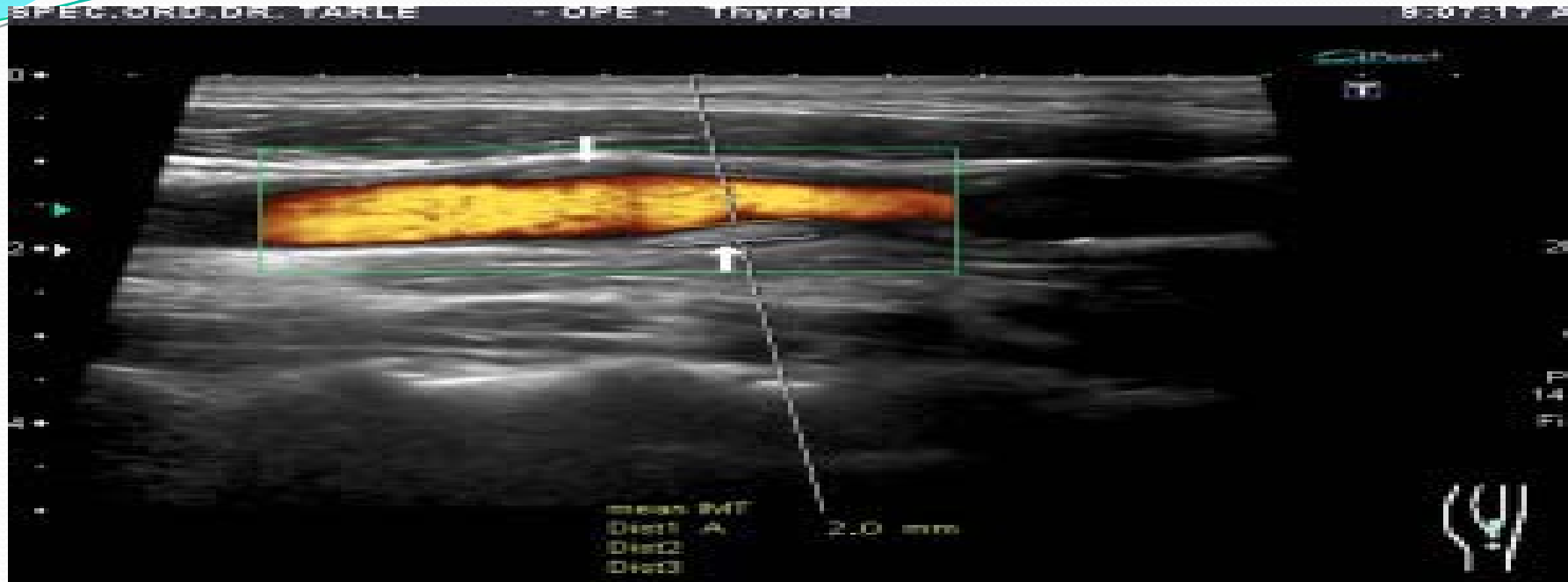
- Sematski prikaz na tromb vo lumenot na VCI

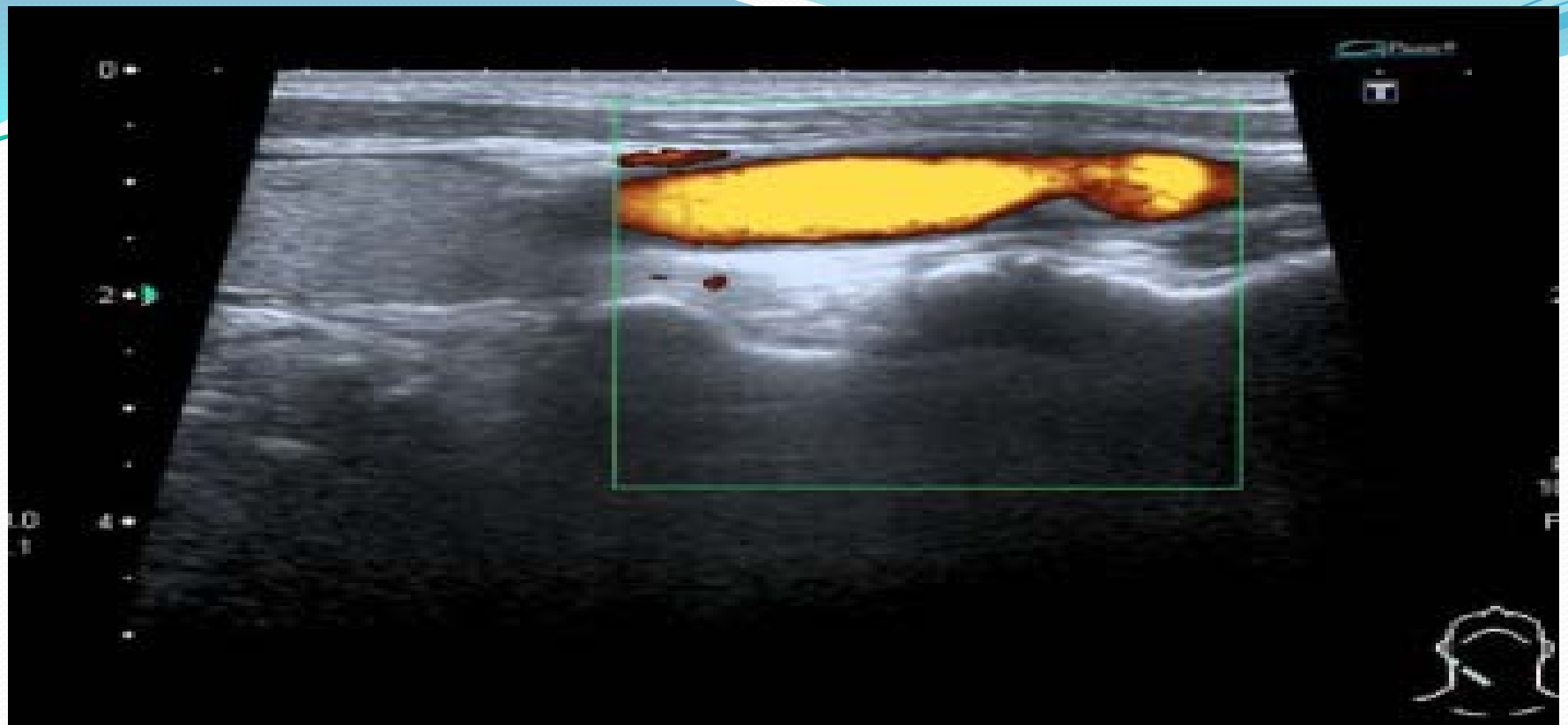


- Sematski prikaz na renalna arterija kaj transplatiran bubreg

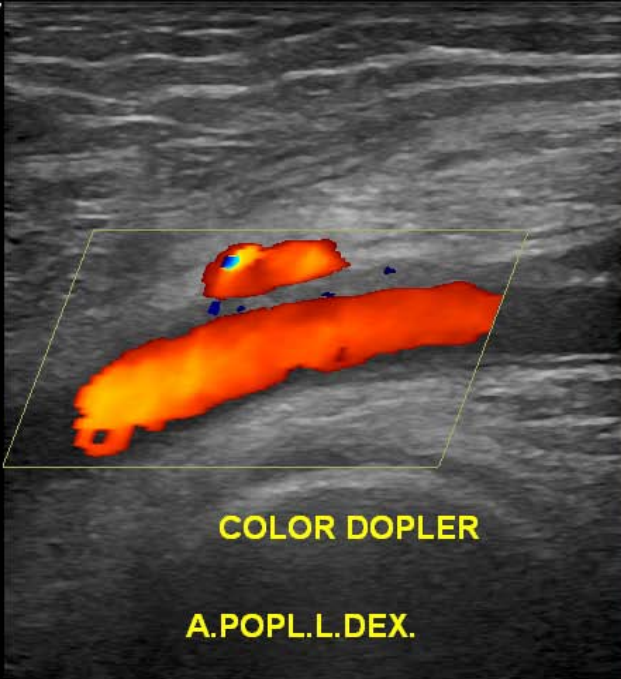



- Sematski prikaz na distalna stenoza na ACI



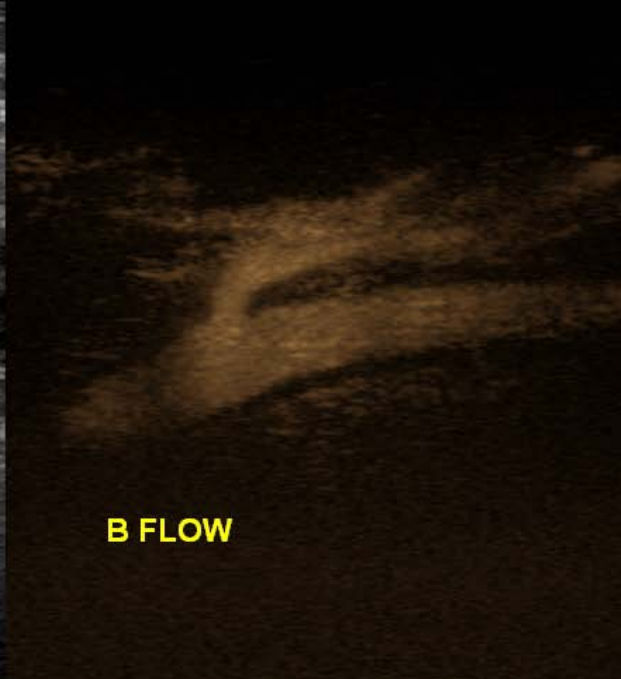


LS7
Exp



COLOR DOPLER

A.POPL.L.DEX.



B FLOW



Za vreme na prestopot vo Bolnica Tokuda – Sofija , R. Bugarija gi obrabotivme gorenavedenite slajdovi.

Istite se prezentirani na strucen sastanok pred kolegite vo Klinicka Bolnica – Interno oddelenie – Tetovo na den 17.12.2014

Vi blagodarime za vasata poddrska (Ministerstvo za zdravstvo) sto ni ovozmozivte na ova strucna edukacija koja ke ni bide vo korist I na nasite dragoceni pacienti.

So pocit:

Dr. Snezana Matovic spec. internist

Klinicka Bolnica - Tetovo